

# TECHNOLOGY-ASSISTED AND SUTURELESS MICROVASCULAR ANASTOMOSES: EVIDENCE FOR CURRENT TECHNIQUES

GEORGE F. PRATT, M.B.B.S., PGDipSurgAnat, WARREN M. ROZEN, M.B.B.S., BMed.Sc., PGDipSurgAnat, Ph.D., ANGIE WESTWOOD, B.Sc., ANGELA HANCOCK, M.B.B.S., B.Sc. (Hons), M.R.C.S., DANIEL CHUBB, M.B.B.S., MARK W. ASHTON, M.B.B.S., M.D., F.R.A.C.S., and IAIN S. WHITAKER, B.A. (Hons), M.A. Cantab, M.B.B.Chir, M.R.C.S. F.R.C.S. Ph.D.\*

**Background:** Since the birth of reconstructive microvascular surgery, attempts have been made to shorten the operative time while maintaining patency and efficacy. Several devices have been developed to aid microsurgical anastomoses. This article investigates each of the currently available technologies and attempts to provide objective evidence supporting their use. **Methods:** Techniques of microvascular anastomosis were investigated by performing searches of the online databases Medline and Pubmed. Returned results were assessed according to the criteria for ranking medical evidence advocated by the Oxford Centre for Evidence Based Medicine. Emphasis was placed on publications with quantifiable endpoints such as unplanned return to theatre, flap salvage, and complication rates. **Results:** There is a relative paucity of high-level evidence supporting any form of assisted microvascular anastomosis. Specifically, there are no randomized prospective trials comparing outcomes using one method versus any other. However, comparative retrospective cohort studies do exist and have demonstrated convincing advantages of certain techniques. In particular, the Unilink™/3M™ coupler and the Autosuture™ Vessel Closure System® (VCS®) clip applicator have been shown to have level 2b evidence supporting their use, meaning that the body of evidence achieves a level of comparative cohort studies. **Conclusion:** Of the available forms of assisted microvascular anastomoses, there is level 2b evidence suggesting a positive outcome with the use of the Unilink™/3M™ coupler and the Autosuture™ VCS® clip applicator. Other techniques such as cyanoacrylates, fibrin glues, the Medtronic™ U-Clip®, and laser bonding have low levels of evidence supporting their use. Further research is required to establish any role for these techniques. © 2011 Wiley Periodicals, Inc. *Microsurgery* 00:000–000, 2011.

The French vascular surgeon Alexis Carrel challenged the widely held belief that vascular anastomosis was not possible in 1902. He pioneered new techniques such as the triangulation of vessels, the use of sharp round bodied needles to minimize intimal damage, and irrigation with crystalloid to perform the first successful anastomosis.<sup>1</sup> Many of his ideas are still used today, and he won a Nobel Prize in recognition of his work in 1912.

Reconstructive microvascular surgery as we understand it today—the anastomosis of vessels a few millimeters in diameter using microscopic assistance—was born in 1960 when Jules Jacobson, of the University of Vermont, carried out the first microvascular surgery, coupling vessels as small as 1.4 mm diameter. Since then, technical advances allowing anastomosis of successively smaller blood vessels and nerves have been central to the development of the microsurgical field.<sup>2</sup> Innovations in reconstructive microsurgery followed swiftly during the 1960s and 1970s. The first publication by Buncke<sup>3</sup> reported a successful rabbit ear replantation, requiring

union of vessels of 1 mm in size. Then, in 1968, Cobbett<sup>4</sup> performed the first human microsurgical transplantation of the great toe to the thumb.

Microsurgery moved from the experimental to the mainstream with the development of specialized microsurgical instruments. These included fine-tipped toothed forceps designed to produce minimal intimal damage to the vessel, accurate sharp microsurgical scissors, fine vessel dilators, and an array of microclamps available in single and double configurations. Recently, the microsurgeons' tray has been supplemented with microvessel clips and suction pads. The goal of faster, more stable microvascular anastomoses continues to drive innovation and scientific progress in the field of microsurgery.

Modern microsurgical suturing techniques involve the use of fine (8/0–12/0) monofilament nylon sutures mounted on sharp round-bodied needles. The vessel is prepared under the microscope—clean perpendicular cuts are made to the ends for anastomosis using sharp microscissors and the adventitia is trimmed. The lumens are cleaned using heparinized crystalloid and if necessary gently dilated using vessel dilators. Often the vessels to be anastomosed are mounted in a double clamp such that the ends can be approximated under no tension. Suturing then proceeds with minimal luminal handling. This technique has been refined allowing successful anastomosis of vessels with significant size mismatch and also allowing end to side anastomosis.<sup>5</sup>

The development of reliable microanastomotic techniques facilitated a revolution in reconstructive surgery. The importation of remote tissue using the microvascular anastomosis provided a new solution where previous

---

Jack Brockhoff Reconstructive Plastic Surgery Research Unit, Department of Anatomy and Cell Biology, University of Melbourne, Melbourne, Vic., Australia

Institutional Ethical Approval was obtained prospectively for the studies reviewed in this article and conforms to the provisions of the Declaration of Helsinki in 1995.

\*Correspondence to: Iain S Whitaker, B.A. (Hons), M.A. Cantab, M.B.B.Chir, M.R.C.S., F.R.C.S., Ph.D., Jack Brockhoff Reconstructive Plastic Surgery Research Unit, Room E533, Department of Anatomy, University of Melbourne, Grattan Street, Parkville, 3050, Victoria, Australia. E-mail: iainwhitaker@fastmail.fm

Received 11 January 2011; Accepted 12 May 2011

Published online in Wiley Online Library (wileyonlinelibrary.com). DOI 10.1002/micr.20930

obstructions to local reconstruction might have existed. Today free tissue transfer is widely used in breast reconstruction, head and neck reconstruction, and lower limb trauma.

Despite the advances that resulted in reproducible microvascular anastomoses, the technique of sutured anastomosis necessarily involves an inherent degree of handling of the vessel including the intima. In addition, there remains intraluminal foreign material in the form of nylon sutures. These and other factors result in a persistent failure rate of sutured microvascular anastomoses in the order of 2–6%.<sup>6,7</sup> This is often as a result of thrombosis. Furthermore, even in experienced hands, microvascular anastomosis remains a challenging and time consuming procedure and has a steep learning curve for the training surgeon. For these reasons, alternatives to the traditional sutured microvascular anastomosis have been actively investigated in recent times. Forms of assisted microvascular anastomosis currently in use include coupling devices, clipping or stapling devices, various adhesives, and laser bonding techniques.

The purpose of this article is to review all major publications regarding innovative methods of microsurgical anastomosis and to determine the level of evidence existing to support their use.

## METHODS

The evidence for technology-assisted microvascular anastomoses to improve operative times and outcomes with safety was investigated by literature review. For inclusion in this review, papers were required to meet the following criteria: case series or higher in terms of construction, be published during the period 1991–2010 (inclusive), be within the field of reconstructive microvascular surgery, and be studies in humans.

Studies for inclusion were identified using the online databases PubMed and Medline. Boolean operators were used to link keywords such as “anastomosis AND coupler,” “microsurgery AND coupler,” “Unilink™ AND anastomosis,” “VCS® clip,” “clip AND microsurgery,” “clip AND anastomosis,” “staple AND microsurgery,” “glue AND microsurgery,” “glue AND anastomosis,” “laser AND microsurgery,” “laser AND anastomosis,” and “photochemical AND anastomosis.” This returned a very significant number of results ( $n = 6,136$ ) including many from specialties such as neurosurgery, cardiac surgery, urology, and general surgery. This approach was made to ensure that no relevant papers were omitted from consideration. Secondary search was performed limiting this number to studies in the date from 1991 to 2010 and in English ( $n = 3,143$ ). Article title search was performed within the citation manager to exclude papers clearly from other specialties. This was achieved by filtering by keywords

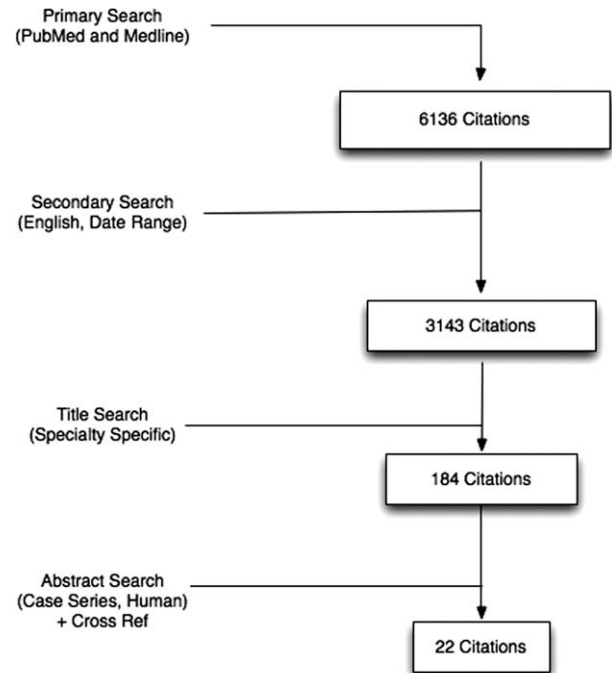


Figure 1. Citation attrition diagram documenting search process.

such as ophthalmic or hepatic and removing the citations followed by manual filtering. The resulting 184 studies were assessed by abstract and cross-referencing resulting in 22 papers meeting inclusion criteria.<sup>8–29</sup> Figure 1 shows a citation attrition chart of the search process, and Tables 1 and 2 show an illustrative although not exhaustive sample of the reviewed papers. References to papers not meeting inclusion criteria (e.g., animal studies) are included for discussion purposes only. Although all series meeting inclusion criteria were assessed regardless of construction, emphasis was placed, in the discussion, on papers with control groups investigating quantifiable endpoints. These studies are assessed for gross errors of construction and subsequently attributed a CEBM (Centre for Evidence Based Medicine) evidence level. The CEBM (<http://www.cebm.net>) attributes levels of evidence ranging from levels 1 (randomized control trial [RCT] or meta-analysis of RCTs) to 5 (expert opinion) to any given research paper.

## RESULTS

### Coupler

The Unilink/3M™ Microvascular Anastomotic Coupler<sup>30</sup> was developed in the 1960s.<sup>31</sup> Ring-type couplers use two rings with interlocking metal pins and reciprocal holes. Each end of the vessels for anastomosis is passed through the ring and reflected back over the pins. The two rings are then pressed together until a clip is engaged (Figs. 2–4). The rings were initially thought to

Table 1. Major Clinical Series Reporting Use of Microvascular Coupler

	Number of anastomoses	Veins and Arteries?	Failures	Salvage rate	Average anastomosis time	Notes	Case mix
Ahn et al. <sup>13</sup>	123	Yes	2 (1.6%)	100%	4 min	Only 24 arteries (the rest were sutured)	Breast, head/neck, limb trauma
Nishimoto et al. 2000 <sup>14</sup>	121	Veins only	0	NA	'Most less than 5 min'	One take back for congestion but anastomosis was found to be patent	Head/neck
Spector et al. <sup>16</sup> (Senior Author Ahn)	? (80 flaps)	Yes	1 (1.3%)	100%	Not specified	Used elastic strip, able to successfully complete arterial anastomosis 80% of cases	Breast
Zeebregts et al. <sup>8</sup>	161	Veins only	7 (5%); failure rate for sutured veins was 6%		9 min (significantly faster than sutures)	Compared sutures to coupler (and to VCS)	Breast, head/neck, limb trauma
Chernichenko et al. <sup>17</sup>	124 (out of 127, three were unable to be coupled)	Only <b>arteries</b> reported although suggests veins were anastomosed as well	4 (3.2%) arterial failures (overall flap failure 2.4%)	75%	Not reported	Able to successfully complete coupling of arteries in 98% of cases	Head and neck
Rozen et al. <sup>11</sup>	1,000 (of 2,500)	Veins and arteries	29 (2.9%)	Unclear	4 min (significantly faster than sutures)	Large studies comparing suture, coupled and clipped arms	Breast, head/neck, limb trauma
Jandali et al. <sup>25</sup>	1,000	Veins only	6 (0.6%)	Unclear	3 min (only measured in 20 cases)	Large series, however, no control arm	Breast

**Table 2.** Major Clinical Series Reporting Use of VCS<sup>®</sup> Clip Applicator

	Number of anastomoses	Veins & Arteries?	Failures	Salvage rate	Average anastomosis time	Notes	Case mix
Zeebregts et al. <sup>8</sup>	110	Yes	1 (2% of all clipped venous; failure rate for sutured veins was 6%)	58%	17 min (significantly faster than sutures)	Compared sutures to coupler (and to VCS)	Breast, head/neck, limb trauma
Cope et al. <sup>9</sup>	153	Yes	No failures	NA	Comment on learning curve— as low as 5 minutes	Comment on need for trained assistant	Breast, head/neck, limb, trunk
Lorenzi et al. <sup>9</sup>	Not specified—26 flaps	Yes	No failures	NA	Not specified—'quick'	Comment that in their experience VCS is superior to Unilink for size mismatch	Lower limb reconstruction
Rozen et al. <sup>11</sup>	400	Yes	20 (5%)	Unclear	15 min (significantly faster than sutures but slower than coupler)		Breast, head/neck, limb trauma

be only suitable for anastomosing pliable-walled vessels of equal size match (i.e., well matched veins).

As early as 1985, ring-type couplers were being used in small series<sup>32</sup> and over the last two decades their use has become progressively more common. Some prominent authors advocate their use for venous and arterial anastomoses.<sup>13,16,17,19</sup> There is a significant body of literature demonstrating faster and easier microanastomoses and a shorter learning curve when these devices are used.<sup>8,11,13,14,16–18,20–22,25,33</sup> Statistically similar patency rates have been found as compared to traditional sutured anastomoses.<sup>8,11,13–18,20–24,34</sup> Anastomotic strength has been tested in animal models and found to generally exceed that of traditional anastomoses.<sup>35</sup> One of the inherent benefits of anastomoses created using coupling devices is the absence of any intraluminal foreign material, which might be a nidus for thrombus formation. Critics of the coupler suggest that because of the penetrative nature of the device, the thrombogenic subendothelial collagen matrix may become exposed.

Although early reports suggested that the use of the coupler (particularly for arterial anastomoses) may be suboptimal in irradiated fields in head and neck surgery,<sup>22</sup> more recent series<sup>19</sup> and animal studies<sup>36</sup> suggest otherwise.

At least two reports exist for a possible foreign body sensation associated with the use of the coupler in the digits, possibly requiring removal of the device,<sup>37,38</sup> and one report demonstrates the possibility of delayed removal of the device without negative consequences.<sup>39</sup>

Two very large series have been recently published, which provide further evidence for the use of the coupler. Rozen et al.<sup>11</sup> compared 1,000 coupled venous anastomoses to 1,100 sutured anastomoses in breast, head and

neck, and lower limb reconstruction and showed a statistically significant reduction in time to anastomosis as well as excellent success rates. Jandali et al.<sup>25</sup> published a series of 1,000 consecutive venous anastomoses in breast reconstruction using the Synovis<sup>TM</sup> coupler. Although this series had no control arm, a venous thrombosis rate of 0.6% was reported.

The results regarding anastomotic coupling devices are summarized in Table 1.

### Clips

Autosuture<sup>TM</sup> developed the second-generation anastomotic aid—the Vessel Closure System<sup>®</sup> (VCS<sup>®</sup>) in 1995. The proposed benefit of this system is a clipped anastomosis that results in the absence of intraluminal foreign material and has a theoretical lower rate of thrombosis.

The clip applicator is used by initially placing a variable number of “stay sutures” around the anastomosis in a conventional manner. The edges of the anastomosis are then everted using a specialized everting forceps and a variable number of clips are placed around the circumference. In the event of a clip being placed incorrectly, it is easily removed with the use of a specialized tool. As the clips are placed at variable distance, discrepancy in size match of the two vessels can be accommodated. Various sizes of clip are available, the selection determined by the thickness of the vessel wall rather than the diameter of the vessel.

A large body of animal experimental research exists which demonstrates that the VCS<sup>®</sup> clip applicator is fast and produces little histological reaction in the vessels anastomosed.<sup>40–44</sup> It has been shown to be effective in






Figure 2. The vessel walls are reflected onto the prongs of the device. [Color figure can be viewed in the online issue, which is available at [wileyonlinelibrary.com](http://wileyonlinelibrary.com).]

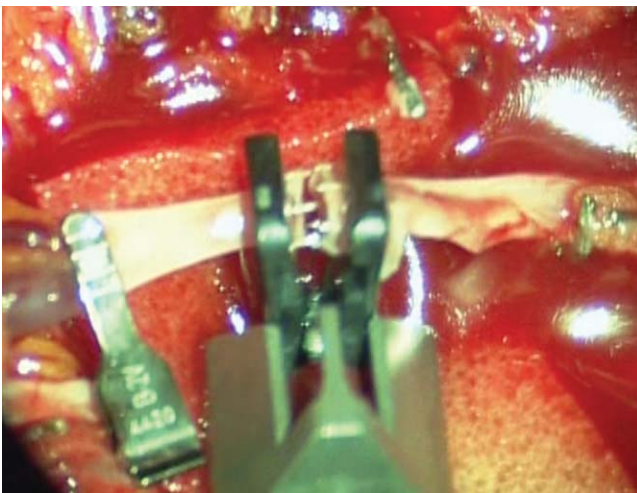


Figure 3. The two rings are approximated. [Color figure can be viewed in the online issue, which is available at [wileyonlinelibrary.com](http://wileyonlinelibrary.com).]

both end-to-end and end-to-side anastomoses.<sup>9,10,45–47</sup> Large series by Zeebregts and Cope<sup>8,9,46,48,49</sup> and numerous review articles have established clipped anastomoses as faster and safe when compared with conventional sutured anastomoses. When compared with conventional anastomoses, patency rates have been shown to be at least equal, and some histological studies have demonstrated faster healing, attributed to the absence of intraluminal foreign material and better intima to intima contact. Rozen et al.<sup>11</sup> recently published a very large series in which the VCS<sup>®</sup> device was used in 400 anastomoses with excellent results in a variety of clinical applications.

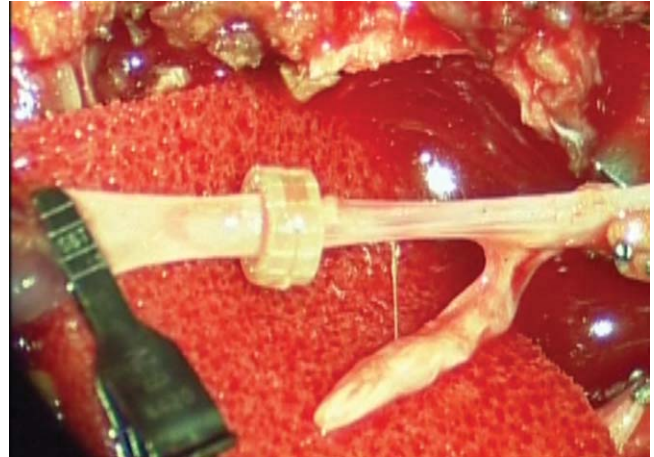


Figure 4. The completed anastomosis. [Color figure can be viewed in the online issue, which is available at [wileyonlinelibrary.com](http://wileyonlinelibrary.com).]

A newer clipping device—the Medtronic<sup>™</sup> U-Clip<sup>®</sup>—uses a clip mounted on a penetrating needle. As with sutures, this device results in foreign material within the lumen of the anastomosis and thus does not have the theoretical benefit of the VCS<sup>®</sup> with no intraluminal foreign material. Nonetheless, the U-Clip<sup>®</sup> is significantly faster to use when compared with traditional anastomoses. Although this device has shown promise in cardiac surgery, there exist few reports<sup>50</sup> of its use in reconstructive microsurgery. It has, however, been compared favorably to other mechanical anastomotic aides in a small series.<sup>51</sup> The results regarding the VCS clip applicator are summarized in Table 2.

### Adhesives

The use of adhesives in surgery has gathered more interest in recent times. Currently available surgical adhesives can be broken into two groups—cyanoacrylates and the so-called “fibrin glues.” Cyanoacrylates have long been used by emergency departments and general practitioners to close minor wounds, particularly in pediatric populations. Various other uses have been reported in the literature including roles in microvascular reconstructive surgery.

Thrombin-based fibrin glues such as Tisseel<sup>®</sup> and Tissucol<sup>®</sup> continue to generate interest in terms of novel surgical applications. In theory, these substances could be used for sutureless anastomoses and also for stabilizing anastomoses and plugging minor leaks after conventional anastomoses. Certainly the use of these products in anastomosing other structures such as vas deferens, nerves, and hollow viscus is well reported in the literature.<sup>52–57</sup> However, concerns regarding the inherent thrombogenicity of these products and the potential for triggering intraluminal thrombosis exist.<sup>58</sup> Although promising animal

studies have been published,<sup>59–64</sup> few clinical series exist. At least one large series of free tissue transfers in breast reconstruction ( $n = 349$ ) reports use of thrombin-based glues with no apparent increase in anastomotic failure.<sup>65</sup> A cohort study in 2009 compared sutured anastomoses with or without fibrin glue.<sup>66</sup> It was found that the fibrin glue group had faster anastomotic times and used reduced number of sutures. Outcomes were similar although the two groups were small. In addition, a series of 36 digital replants using reduced sutures and fibrin sealant was reported by Isogai et al.<sup>28</sup> This series used a reduced number of sutures and fibrin sealant was applied to the anastomoses. An overall failure rate of 11% was reported, consistent with other studies. A small series reporting the use of fibrin glues to stabilize pedicles and prevent kinking showed no increased rate of thrombotic anastomotic complications.<sup>29</sup>

Various potential uses of cyanoacrylate adhesives have been reported in animal studies ranging from completely sutureless anastomoses with glue only<sup>67</sup> or glue with absorbable biostents<sup>67,68</sup> to reduced suture anastomoses with adhesive and hemostasis.<sup>69–72</sup> Although these studies have gone some way to demonstrate safety and increased speed and reliability of anastomoses, some studies have shown significant histological foreign body reactions in vessels walls.<sup>73</sup>

One report in the literature advocates use of a coating of cyanoacrylate to give collapsed veins added rigidity thereby reducing the risks of suturing the back wall<sup>74</sup> and at least one report of using cyanoacrylates as haemostatic agent in anastomoses in humans exists.<sup>75</sup> Although some of these reports are letters referring to human surgical practices, there are no published series supporting the benefits or safety of cyanoacrylates in microvascular reconstructive surgery.

### Laser and Photochemical-Assisted Anastomoses

Interest began to develop in the use of lasers in microsurgical anastomoses in the early 1980s.<sup>76</sup> Since then many studies investigating various lasers (e.g., carbon dioxide, argon, thulium–holmium–chromium) for thermal bonding of microvascular anastomoses have been reported,<sup>77–90</sup> although descriptions of use in clinical practice remain limited. Most recently, interests in Excimer<sup>®</sup> laser-assisted nonocclusive anastomoses in neurosurgery<sup>91–95</sup> and the use of the KTP-532 laser for microsurgical anastomoses<sup>96</sup> have emerged. Laser-assisted thermal bonding for neural reconstruction<sup>97,98</sup> and the use of photochemical bonding using visible spectrum light and photoactive dyes<sup>99</sup> have been described.

A solitary clinical paper by Leclère et al.<sup>27</sup> reports perhaps the first use of laser microanastomoses in clinical use in reconstructive surgery. In this series, 27 patients underwent 58 anastomosis with the use of a 1.9 micron

diode laser to perform welded reduced suture anastomoses. Generally, four sutures were still applied to achieve apposed edges. This study included arteries and veins and both end-to-end and end-to-side anastomoses. A single case of anastomosis failure was reported (1.7%) in which an arterial anastomosis “ruptured,” possibly due to the anastomosis being in irradiated tissue. Anastomotic time was not measured but was considered anecdotally to be reduced. There was no control arm in this study.

### DISCUSSION

While a meticulously sutured microvascular anastomosis remains a standard practice, there is a growing body of evidence supporting the use of coupling and clipping devices. Many units have adopted the use of these devices and report significant advantages in terms of speed and ease of use over traditional anastomoses. Where previously these devices were thought to have applications limited to certain situations such as easier venous anastomoses, innovators in the field have challenged these ideas and shown potential use in arterial anastomoses, end-to-side anastomoses, and even in irradiated tissue. Detractors of these devices have supported that reducing the surgeon’s exposure to traditional sutured anastomoses could result in dangerous de-skilling, pointing out that particularly challenging anastomoses are often not amenable to the current devices anyway. In addition, issues of potential selection bias in many of the series is invoked—namely that the device is often used on easier anastomoses and then compared to sutured anastomoses which were the remaining more technically challenging vessels. Despite these concerns it is likely that there is a genuine role for these devices in accelerating microsurgery. As the cost of couplers and clipping systems falls, the cost savings associated with speedier surgeries will make the cost benefit ratio increasingly favorable. Currently, the evidence supporting the use of both the Unilink<sup>™</sup> Coupler and the VCS<sup>®</sup> clip applicator has achieved level 2b as defined by the Oxford CEBM. This implies that well-constructed, cohort-controlled studies demonstrating a benefit for these techniques exist.

Currently, there is little evidence beyond small series supporting glues and laser-assisted bonding in microsurgery save for one small sample cohort study by Cho et al.<sup>66</sup> However, advances in either of these fields could in the future see completely sutureless anastomoses with little or no handling of the vessels. In addition, recent interest in robotics in other branches of surgery has spilled over into microsurgery with proof of concept papers reporting successful use of robots in experimental microsurgical models.<sup>100,101</sup> Other completely sutureless techniques using bioabsorbable stents and glues are also being investigated.<sup>102</sup> Until such time as these technologies are

established, the humble sutured microvascular anastomosis, with or without the use of couplers and clipping devices will remain the norm.

## CONCLUSIONS

There is level 2b evidence supporting the use of the Unilink™/3M™ anastomotic coupler and the Autosuture™ VCS® clip applicator in a wide variety of microvascular anastomoses including end-to-side, arterial anastomoses, and anastomoses in irradiated fields. Glues including cyanoacrylates and fibrin glues have scant evidence associated with their use in any capacity be it sutureless anastomoses or adjuncts to reduced suture anastomoses. Laser and photochemical bonded anastomoses have virtually no clinical evidence associated with their use in microvascular anastomoses save for one small series. All the above technologies would benefit from further high quality research to definitively establish their role in the microsurgeon's armamentarium.

## REFERENCES

- Carrel A. Operative technique of vascular anastomoses and visceral transplantation. *Lyon Med* 1964;212:1561–1568.
- Kleinert HE, Kasdan ML. Restoration of blood flow in upper extremity injuries. *J Trauma* 1963;3:461–476.
- Buncke HJ, Schulz WP. Total ear reimplantation in the rabbit utilizing microminature vascular anastomoses. *Br J Plast Surg* 1966;19:15–22.
- Cobbett JR. Free digital transfer. Report of a case of transfer of a great toe to replace an amputated thumb. *J Bone Joint Surg Br* 1969;51:677–679.
- Alghoul MS, Gordon CR, Yetman R, Buncke GM, Siemionow M, Afifi AM, Moon WK. From simple interrupted to complex spiral: A systematic review of various suture techniques for microvascular anastomoses. *Microsurgery* 2011;31:72–80.
- Disa JJ, Cordeiro PG, Hidalgo DA. Efficacy of conventional monitoring techniques in free tissue transfer: An 11-year experience in 750 consecutive cases. *Plast Reconstr Surg* 1999;104: 97–101.
- Bui DT, Cordeiro PG, Hu QY, Disa JJ, Pusic A, Mehrara BJ. Free flap reexploration: Indications, treatment, and outcomes in 1193 free flaps. *Plast Reconstr Surg* 2007;119:2092–2100.
- Zeebregts C, Acosta R, Bölander L, van Schilfgaarde R, Jakobsson O. Clinical experience with non-penetrating vascular clips in free-flap reconstructions. *Br J Plast Surg* 2002;55:105–110.
- Cope C, Lee K, Stern H, Pennington D. Use of the vascular closure staple clip applicator for microvascular anastomosis in free-flap surgery. *Plast Reconstr Surg* 2000;106:107–110.
- De Lorenzi F, van der Hulst RR, Boeckx WD. VCS auto suture stapled microvascular anastomoses in lower leg free flaps. *Plast Reconstr Surg* 2002;109:2023–2030.
- Rozen WM, Whitaker IS, Acosta R. Venous coupler for free-flap anastomosis: Outcomes of 1,000 cases. *Anticancer Res* 2010;30: 1293–1294.
- Baynosa RC, Stutman R, Mahabir RC, Zamboni WA, Khiabani KT. Use of a novel penetrating, sutureless anastomotic device in arterial microvascular anastomoses. *J Reconstr Microsurg* 2008;24:39–42.
- Ahn CY, Shaw WW, Berns S, Markowitz BL. Clinical experience with the 3M microvascular coupling anastomotic device in 100 free-tissue transfers. *Plast Reconstr Surg* 1994;93:1481–1484.
- Nishimoto S, Hikasa H, Ichino N, Kurita T, Yoshino K. Venous anastomoses with a microvascular anastomotic device in head and neck reconstruction. *J Reconstr Microsurg* 2000;16:553–556.
- Chang K-P, Lin S-D, Lai C-S. Clinical experience of a microvascular venous coupler device in free tissue transfers. *Kaohsiung J Med Sci* 2007;23:566–572.
- Spector JA, Draper LB, Levine JP, Ahn CY. Routine use of microvascular coupling device for arterial anastomosis in breast reconstruction. *Ann Plast Surg* 2006;56:365–368.
- Chernichenko N, Ross DA, Shin J, Sasaki CT, Ariyan S. End-to-side venous anastomosis with an anastomotic coupling device for microvascular free-tissue transfer in head and neck reconstruction. *Laryngoscope* 2008;118:2146–2150.
- Camara O, Herrmann J, Egbe A, Koch I, Gajda M, Runnebaum IB. Venous coupler for free-flap anastomosis. *Anticancer Res* 2009; 29:2827–2830.
- Ross DA, Chow JY, Shin J, Restifo R, Joe JK, Sasaki CT, Ariyan S. Arterial coupling for microvascular free tissue transfer in head and neck reconstruction. *Arch Otolaryngol Head Neck Surg* 2005;131:891–895.
- Denk MJ, Longaker MT, Basner AL, Glat PM, Karp NS, Kasabian AK. Microsurgical reconstruction of the lower extremity using the 3M microvascular coupling device in venous anastomoses. *Ann Plast Surg* 1995;35:601–606.
- de Bruijn HP, Marck KW. Coupling the venous anastomosis: Safe and simple. *Microsurgery* 1996;17:414–416.
- Shindo ML, Costantino PD, Nalbone VP, Rice DH, Sinha UK. Use of a mechanical microvascular anastomotic device in head and neck free tissue transfer. *Arch Otolaryngol Head Neck Surg* 1996;122: 529–532.
- Sasson HN, Stofman GM, Berman P. Clinical use of the 3M 2.5 mm mechanical microcoupling device in free tissue transfer. *Microsurgery* 1994;15:421–423.
- Yap LH, Constantinides J, Butler CE. Venous thrombosis in coupled versus sutured microvascular anastomoses. *Ann Plast Surg* 2006;57:666–669.
- Jandali S, Wu LC, Vega SJ, Kovach SJ, Serletti JM. 1000 consecutive venous anastomoses using the microvascular anastomotic coupler in breast reconstruction. *Plast Reconstr Surg* 2010;125:792–798.
- Andree C, Munder BI, Behrendt P, Hellmann S, Audretsch W, Voigt M, Reis C, Beckmann MW, Horch RE, Bach AD. Improved safety of autologous breast reconstruction surgery by stabilisation of microsurgical vessel anastomoses using fibrin sealant in 349 free DIEP or fascia-muscle-sparing (fms)-TRAM flaps: A two-centre study. *Breast* 2008;17:492–498.
- Leclère FM, Schoofs M, Buys B, Mordon SR. Outcomes after 1.9-microm diode laser-assisted anastomosis in reconstructive microsurgery: Results in 27 patients. *Plast Reconstr Surg* 2010; 125:1167–1175.
- Isogai N, Cooley BG, Kamiishi H. Clinical outcome of digital replantation using the fibrin glue-assisted microvascular anastomosis technique. *J Hand Surg Br* 1996;21:573–575.
- Schwabegger AH, Engelhardt TO, Jeschke J. Stabilization of microvascular pedicles in intricate locations using fibrin glue. *Microsurgery* 2008;28:509–513; discussion 514–515.
- Ostrup LT, Berggren A. The UNILINK instrument system for fast and safe microvascular anastomosis. *Ann Plast Surg* 1986; 17:521–525.
- Nakayama K, Tamiya T, Yamamoto K, Akimoto S. A simple new apparatus for small vessel anastomosis (free autograft of the sigmoid included). *Surgery* 1962;52:918–931.
- Zhou G, Ling YC, Qiao Q. Experience using microvascular anastomotic rings for the transplantation of 20 free flaps. *Plast Reconstr Surg* 1989;84:822–826.
- Zdolsek J, Ledin H, Lidman D. Are mechanical microvascular anastomoses easier to learn than suture anastomoses? *Microsurgery* 2005;25:596–598.
- Ducic I, Brown BJ, Rao SS. Lower extremity free flap reconstruction outcomes using venous coupler. *Microsurgery* 2011 May 31. DOI 10.1002/micr.20888 [Epub ahead of print].
- Gilbert RW, Ragnarsson R, Berggren A, Ostrup L. Strength of microvascular anastomoses: Comparison between the unilink anastomotic system and sutures. *Microsurgery* 1989;10:40–46.
- Ragnarsson R, Berggren A, Klintonberg C, Ostrup L. Microvascular anastomoses in irradiated vessels: A comparison between the Unilink system and sutures. *Plast Reconstr Surg* 1990;85:412–418.



37. Hallock GG. The microanastomotic coupler masquerading as a foreign body. *Plast Reconstr Surg* 2008;122:154e–155e.
38. Kind GM, Buncke GM, Buncke HJ. Foreign-body sensation following 3M coupler use in the hand. *Ann Plast Surg* 1996;37:418–421.
39. Hilliard S, Pommier R, Solomon JS. Delayed removal of 3M vein coupler does not disturb the anastomosis. *Microsurgery* 2009;29:502–503.
40. Klöppel M, Tudor C, Kovacs L, Papadopoulos NA, Höhnke C, Himsel I, Hoang NT, Biemer E. Comparison of experimental microvascular end-to-end anastomosis via VCS-Clips versus conventional suture technique in an animal model. *J Reconstr Microsurg* 2007;23:45–49.
41. Aviles AJ, Theodorou S, Sekosen M, Schraufnagel D, Ramasastry S. Challenging Alexis Carrel: A study in alternate microvascular techniques. *Neurol Res* 2004;26:809–815.
42. Lee JW, Choo SJ, Oh JH, Lee I, Kwon YM, Lee YJ, Lee SK, Song H, Song MG. Anastomosis of vessels less than 2 mm with the vascular clip system clip applicator. *J Korean Med Sci*. 2001;16:303–308.
43. Pikoulis E, Rhee P, Nishibe T, Leppänen AK, Fishback N, Hufnagel HV, Wherry DC, Rich NM. Arterial reconstruction with vascular clips is safe and quicker than sutured repair. *Cardiovasc Surg* 1998;6:573–578.
44. Boeckx WD, Darius O, van den hof B, van Holder C. Scanning electron microscopic analysis of the stapled microvascular anastomosis in the rabbit. *Ann Thorac Surg* 1997;63:S128–S134.
45. Zeebregts CJ, Kirsch WM, van den Dungen JJ, Zhu YH, van Schilf-gaarde R. Five years' world experience with nonpenetrating clips for vascular anastomoses. *Am J Surg* 2004;187:751–760.
46. Zeebregts CJ, Kirsch WM, Reijnen MM, Zhu YH, van den Dungen JJ. Expanding use of nonpenetrating clips in various surgical specialties. *Surg Technol Int* 2005;14:85–95.
47. Pratt GF, Rozen WM, Chubb D, Whitaker IS, Grinsell D, Ashton MW, Acosta R. Modern adjuncts and technologies in microsurgery: An historical and evidence-based review. *Microsurgery* 2010;30:657–666.
48. Zeebregts CJ, Kirsch WM, van den Dungen JJ, van Schilf-gaarde R, Zhu YH. Evolution of staples and clips for vascular anastomoses. *Int Surg* 2004;89:152–160.
49. Zeebregts CJ, van den Dungen JJ, Kalicharan D, Cromhecke M, van der Want J, van Schilf-gaarde R. Nonpenetrating vascular clips for small-caliber anastomosis. *Microsurgery* 2000;20:131–138.
50. Taylor J, Katz R, Singh N. Use of the U-clip for microvascular anastomosis. *Microsurgery* 2006;26:550–551.
51. Baynosa RC, Stutman R, Mahabir RC, Zamboni WA, Khiabani KT. Use of a novel penetrating, sutureless anastomotic device in arterial microvascular anastomoses. *J Reconstr Microsurg* 2008;24:39–42.
52. Campodonico F, Casarico A. Re: Comparison of vasovasostomy with conventional microsurgical suture and fibrin adhesive in rats. *Int Braz J Urol* 2008;34:230.
53. Busato WF, Marquetti AM, Rocha LC. Comparison of vasovasostomy with conventional microsurgical suture and fibrin adhesive in rats. *Int Braz J Urol* 2007;33:829–836.
54. Feldman MD, Sataloff RT, Epstein G, Ballas SK. Autologous fibrin tissue adhesive for peripheral nerve anastomosis. *Arch Otolaryngol Head Neck Surg* 1987;113:963–967.
55. Ho KL, Witte MN, Bird ET, Hakim S. Fibrin glue assisted 3-suture vasovasostomy. *J Urol* 2005;174:1360–1363; discussion 1363.
56. Shekarriz BM, Thomas AJ, Sabanegh E, Kononov A, Levin HS. Fibrin-glue assisted vasoepididymostomy: A comparison to standard end-to-side microsurgical vasoepididymostomy in the rat model. *J Urol* 1997;158:1602–1605.
57. Liu CD, Glantz GJ, Livingston EH. Fibrin glue as a sealant for high-risk anastomosis in surgery for morbid obesity. *Obes Surg* 2003;13:45–48.
58. Marek CA, Amiss LR, Morgan RF, Spotnitz WD, Drake DB. Acute thrombogenic effects of fibrin sealant on microvascular anastomoses in a rat model. *Ann Plast Surg* 1998;41:415–419.
59. Whitlock EL, Kasukurthi R, Yan Y, Tung TH, Hunter DA, Mackinnon SE. Fibrin glue mitigates the learning curve of microneurosurgical repair. *Microsurgery* 2010;30:218–222.
60. Cho AB, Júnior RM. Effect of fibrin adhesive application in microvascular anastomosis: A comparative experimental study. *Plast Reconstr Surg* 2007;119:95–103.
61. Cho AB, Júnior RM. Application of fibrin glue in microvascular anastomoses: Comparative analysis with the conventional suture technique using a free flap model. *Microsurgery* 2008;28:367–374.
62. Padubidri AN, Browne E, Kononov A. Fibrin glue-assisted end-to-side anastomosis of rat femoral vessels: Comparison with conventional suture method. *Ann Plast Surg* 1996;37:41–47.
63. Wadström J, Wik O. Fibrin glue (Tisseel) added with sodium hyaluronate in microvascular anastomosing. *Scand J Plast Reconstr Surg Hand Surg* 1993;27:257–261.
64. Isogai N, Fukunishi K, Kamiishi H. Use of fibrin glue to minimize bleeding of microvascular repairs in hypertensive rats. *Microsurgery* 1992;13:321–324.
65. Andree C, Munder BI, Behrendt P, Hellmann S, Audretsch W, Voigt M, Reis C, Beckmann MW, Horch RE, Bach AD. Improved safety of autologous breast reconstruction surgery by stabilisation of microsurgical vessel anastomoses using fibrin sealant in 349 free DIEP or fascia-muscle-sparing (fms)-TRAM flaps: A two-centre study. *Breast* 2008;17:492–498.
66. Cho AB, Wei TH, Torres LR, Júnior RM, Rugiero GM, Aita MA. Fibrin glue application in microvascular anastomosis: Comparative study of two free flaps series. *Microsurgery* 2009;29:24–28.
67. Lemaire D, Mongeau J, Dorion D. Microvascular anastomosis using histoacryl glue and an intravascular soluble stent. *J Otolaryngol* 2000;29:199–205.
68. Schwaiger N, Wu J, Wright B, Morrissey L, Harris M, Rohanizadeh R. BioWeld<sup>(®)</sup> Tube and surgical glue for experimental sutureless venous microanastomosis. *Br J Surg* 2010;97:1825–1830.
69. Hall WW, Wrye SW, Banducci DR, Ehrlich P. Microvascular anastomosis using 2-octyl cyanoacrylate in the rat femoral artery. *Ann Plast Surg* 2000;44:508–511.
70. Ang ES, Tan KC, Tan LH, Ng RT, Song IC. 2-Octylcyanoacrylate-assisted microvascular anastomosis: Comparison with a conventional suture technique in rat femoral arteries. *J Reconstr Microsurg* 2001;17:193–201.
71. Ong YS, Yap K, Ang ES, Tan KC, Ng RT, Song IC. 2-Octylcyanoacrylate-assisted microvascular anastomosis in a rat model: Long-term biomechanical properties and histological changes. *Microsurgery* 2004;24:304–308.
72. Middleton WG, Matthews W, Chiasson DA. Histoacryl glue in microvascular surgery. *J Otolaryngol* 1991;20:363–366.
73. Green AR, Milling MA, Green AR. Butylcyanoacrylate adhesives in microvascular surgery: An experimental pilot study. *J Reconstr Microsurg* 1986;2:103–105.
74. Uysal AC, Uraloglu M, Orbay H, Ortak T, Sensoz O. An alternative method of vein anastomosis with fibrin glue. *Ann Plast Surg* 2005;54:579–580.
75. Giele H. Histoacryl glue as a hemostatic agent in microvascular anastomoses. *Plast Reconstr Surg* 1994;94:897.
76. Jain KK. Sutureless microvascular anastomosis using a neodymium-yag laser. *J Microsurg* 1980;1:436–439.
77. Sartorius CJ, Shapiro SA, Campbell RL, Klatte EC, Clark SA. Experimental laser-assisted end-to-side microvascular anastomosis. *Microsurgery* 1986;7:79–83.
78. Vale BH, Frenkel A, Trenka-Benthin S, Matlaga BF. Microsurgical anastomosis of rat carotid arteries with the CO<sub>2</sub> laser. *Plast Reconstr Surg* 1986;77:759–766.
79. Neblett CR, Morris JR, Thomsen S. Laser-assisted microsurgical anastomosis. *Neurosurgery* 1986;19:914–934.
80. Gelli R, Pini R, Toncelli F, Chiarugi C, Reali UM. Vessel-wall recovery after diode laser-assisted microvascular anastomosis: Clinical and histologic analysis on long-term follow-up. *J Reconstr Microsurg* 1997;13:199–205.
81. Lewis WJ, Uribe A. Contact diode laser microvascular anastomosis. *Laryngoscope* 1993;103:850–853.
82. McCarthy WJ, LoCicero J, Hartz RS, Yao JS. Patency of laser-assisted anastomoses in small vessels: One-year follow-up. *Surgery* 1987;102:319–326.
83. Travers V, Kanaujia RR, Ochi M, Ikuta Y. Microvascular anastomosis using carbon dioxide (CO<sub>2</sub>) laser: Evaluation by SEM after corrosion cast. *J Reconstr Microsurg* 1987;4:61–67.
84. Ruiz-Razura A, Branfman GS, Lan M, Cohen BE. Laser-assisted microsurgical anastomoses in traumatized blood vessels. *J Reconstr Microsurg* 1990;6:55–59.



85. Ruiz-Razura A, Lan M, Cohen BE. The laser-assisted end-to-side microvascular anastomosis. *Plast Reconstr Surg* 1989;83: 511–517.
86. Ruiz-Razura A, Lan M, Hita CE, Khan Z, Hwang NH, Cohen BE. Bursting strength in CO<sub>2</sub> laser-assisted microvascular anastomoses. *J Reconstr Microsurg* 1988;4:291–296.
87. Bass LS, Treat MR, Dzakonski C, Trokel SL. Sutureless microvascular anastomosis using the THC:YAG laser: A preliminary report. *Microsurgery* 1989;10:189–193.
88. He FC, Wei LP, Lanzetta M, Owen ER. Assessment of tissue blood flow following small artery welding with an intraluminal dissolvable stent. *Microsurgery* 1999;19:148–152.
89. Maitz PK, Trickett RI, Dekker P, Tos P, Dawes JM, Piper JA, Lanzetta M, Owen ER. Sutureless microvascular anastomoses by a biodegradable laser-activated solid protein solder. *Plast Reconstr Surg* 1999;104:1726–1731.
90. Nakamura T, Fukui A, Maeda M, Kugai M, Inada Y, Teramoto N, Ishida A, Tamai S. Microvascular anastomoses using an Nd-YAG laser. *J Reconstr Microsurg* 2000;16:577–584.
91. Streefkerk HJ, Bremmer JP, van Weelden M, van Dijk RR, de Winter E, Beck RJM, Tulleken CAF. The excimer laser-assisted nonocclusive anastomosis practice model: Development and application of a tool for practicing microvascular anastomosis techniques. *Neurosurgery* 2006;58:ONS148–ONS156; discussion ONS148–ONS156.
92. Streefkerk HJN, Kleinveld S, Koedam ELGE, Bulder MMM, Meel-duk HD, Verdaasdonk RM, Beck RJM, van der Zwan B, Tulleken CAF. Long-term reendothelialization of excimer laser-assisted non-occlusive anastomoses compared with conventionally sutured anastomoses in pigs. *J Neurosurg* 2005;103:328–336.
93. Russo G, Rotondo M, Punzo A, Di Napoli D. Excimer laser assisted non-occlusive anastomosis (ELANA). Our experience with a training model in vivo. *J Neurosurg Sci* 2007;51:11–16.
94. Muench E, Meinhardt J, Schaeffer M, Schneider U, Czabanka M, Luecke T, Schmiedek P, Vajkoczy P. The use of the excimer laser-assisted anastomosis technique alleviates neuroanesthesia during cerebral high-flow revascularization. *J Neurosurg Anesthesiol* 2007; 19:273–279.
95. Langer DJ, Van Der Zwan A, Vajkoczy P, Kivipelto L, Van Doormaal TP, Tulleken CAF. Excimer laser-assisted nonocclusive anastomosis. An emerging technology for use in the creation of intracranial–intracranial and extracranial–intracranial cerebral bypass. *Neurosurg Focus* 2008;24:E6.
96. Lorincz BB, Kálmán E, Gerlinger I. KTP-532 laser-assisted microvascular anastomosis (experimental animal study). *Eur Arch Otorhinolaryngol* 2007;264:823–828.
97. Hwang K, Kim SG, Kim DJ. Facial-hypoglossal nerve anastomosis using laser nerve welding. *J Craniofac Surg* 2006;17: 687–691.
98. Hwang K, Kim SG, Kim DJ, Lee CH. Laser welding of rat's facial nerve. *J Craniofac Surg* 2005;16:1102–1106.
99. O'Neill AC, Winograd JM, Zeballos JL, Johnson T, Randolph M, Bujold K, Kochevar I, Redmond R. Microvascular anastomosis using a photochemical tissue bonding technique. *Laser Surg Med* 2007; 39:716–722.
100. Katz RD, Rosson GD, Taylor JA, Singh NK. Robotics in microsurgery: Use of a surgical robot to perform a free flap in a pig. *Microsurgery* 2005;25:566–569.
101. Taleb C, Nectoux E, Liverneaux P. Limb replantation with two robots: A feasibility study in a pig model. *Microsurgery* 2009;29: 232–235.
102. Ueda K, Mukai T, Ichinose S, Koyama Y, Takakuda K. Bioabsorbable device for small-caliber vessel anastomosis. *Microsurgery* 2010; 30:494–501.